

CLINICAL CASE

Improved Diagnosis Confidence and Patient Informed Consent

A case where the new CS 8200 3D Neo Edition from Carestream Dental was utilised to help diagnose and treat impacted wisdom teeth alongside numerous other oral issues in a patient.

By Dr. Hubertus Schindler

Patient Situation

A 30-year-old male patient presented complaining of recurrent pain in his 48. An initial evaluation showed that he had extremely impacted wisdom teeth, especially in the lower jaw (38 and 48) (Fig. 1) with signs of coronal osteolysis which was causing him clinically observable pain. Additionally, his oral hygiene was poor and had resulted in gingivitis and calculus build-up. He had caries in multiple sites (15, 16 and 26) and there were signs of abrasion which suggested that the patient was suffering from bruxism.

A panoramic exam was done to get an overview of the general clinical situation of the patients' mouth.

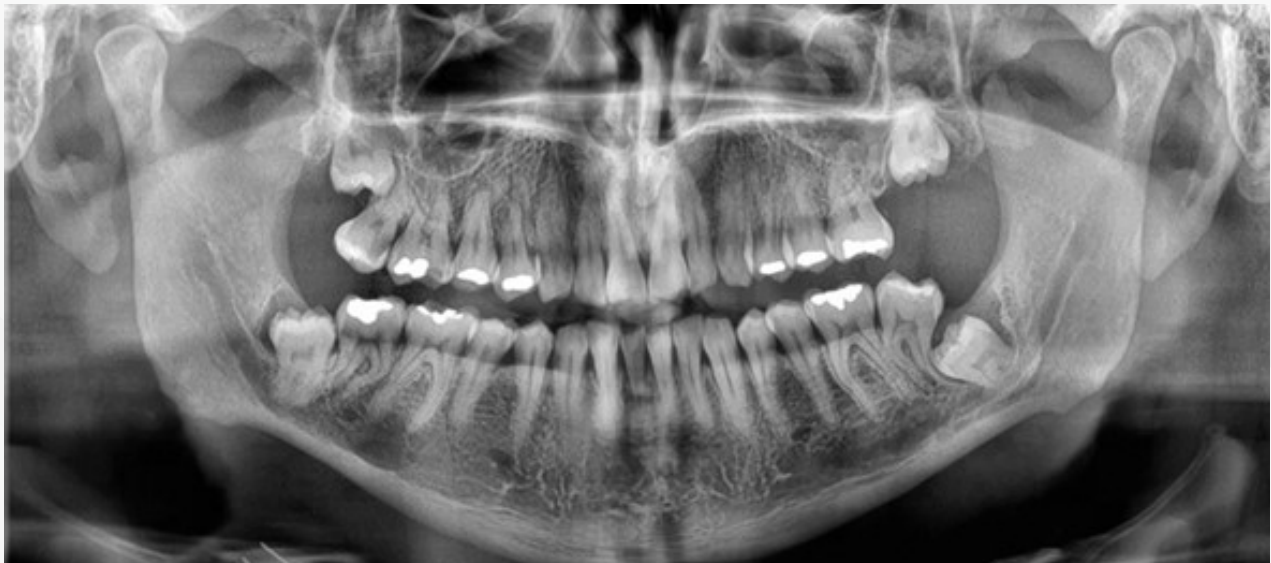

Fig. 1 - Panoramic image clearly showing the impactions of teeth 38 and 48, and their close relationship with the mandibular nerve canals

To identify the extent of the problem, the CS 8200 3D Neo Edition from Carestream Dental was used to obtain volumes for a precise diagnosis. The main benefit of this was the exceptional quality of the X-rays and how these could be used as a powerful communication tool.

“As the images captured so much detail, they helped the patient to understand his medical condition and why the proposed treatment options were necessary. This improved the quality of his informed consent. The system was very easy to use, intuitive, and also helped to streamline the diagnostic workflow due to its fast image acquisition and simple patient positioning.”

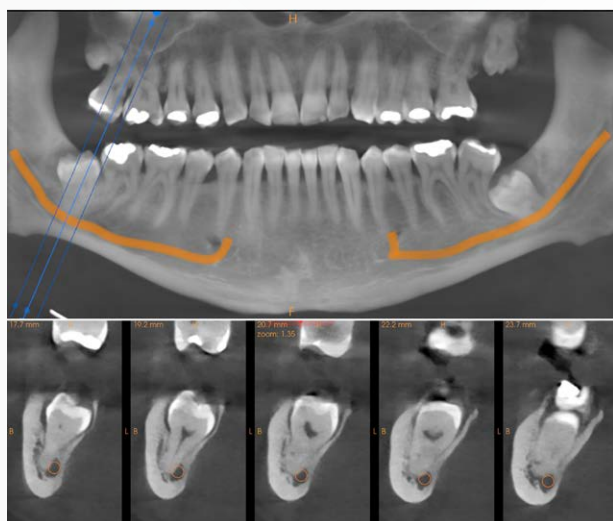


Fig. 2 - Reconstructed panoramic and cross sections of tooth 48, showing the contact of the root with the mandibular nerve canal

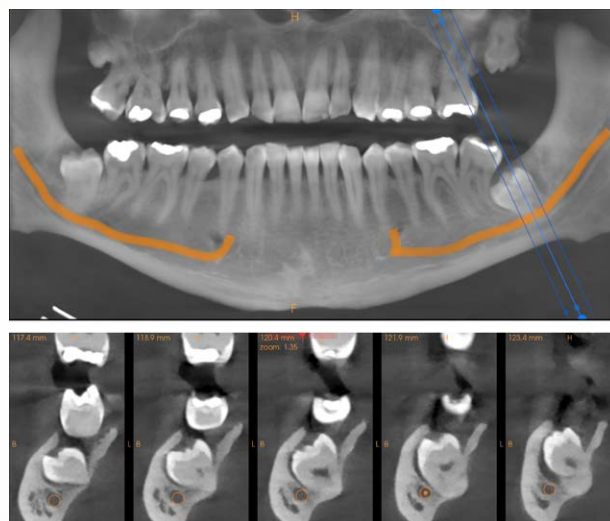


Fig. 3 - Reconstructed panoramic and cross sections of tooth 38, showing the proximity of the tooth with the mandibular nerve canal

Diagnosis and Treatment

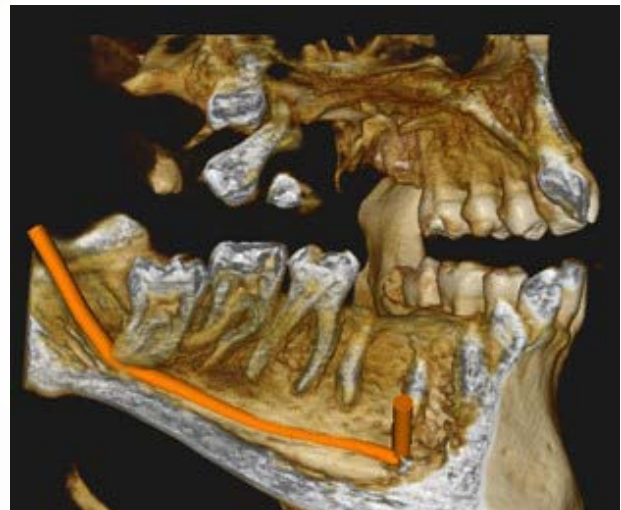
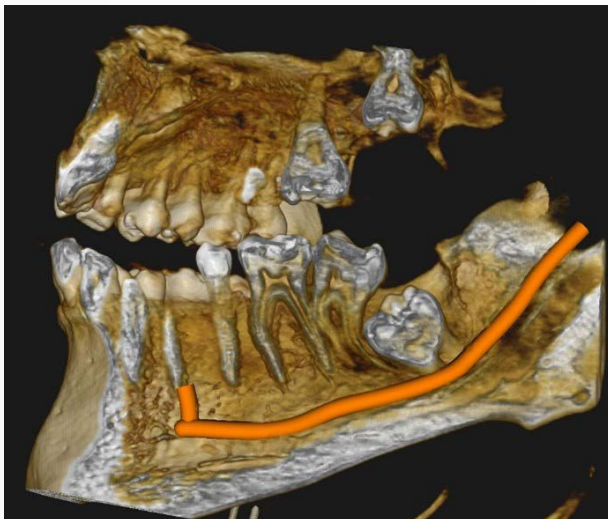
Multiple treatments were recommended based on the findings from the diagnostic images and clinical assessment, including:

1. Parotherapy to help treat the gingivitis and prevent bone loss from progressing any further. This would involve a process of giving the patient a series of thorough tests and questionnaires regarding his oral hygiene habits to assess the extent of the problem, as well as taking images to accurately assess bone structure. Following this, root surface planing is often required and any teeth that cannot be sustained may be removed. The removal of subgingival calculus and any build-up along the gumline would be performed

using special paro instruments and root surfaces would be cleaned and smoothed out. This would usually take 2-4 sessions.

2. Filling therapy for the carious teeth – the teeth at sites 15, 16 and 26 needed fillings to prevent any further decay and existing caries would need to be removed.

3. Wisdom tooth extraction to remove the profoundly impacted wisdom teeth. The patient was warned of any potential damage to the alveolar nerve that extraction could result in.



Figs. 4-5 - 3D scenes showing the complex relationship of teeth 38 (Fig. 4) and 48 (Fig. 5) with their respective mandibular nerve canals

4. A brux splint to help treat the bruxism. This measure would be to prevent further abrasion and damage to the dentition and would require extra appointments in the future for the fitting of the splint.

The patient was informed of the benefits and possible complications associated with each treatment option. Using the images taken by the CS 8200 3D Neo Edition made this part of the process really simple, especially as the images captured had all the detail necessary to aid any conversation surrounding each treatment option and give the patient a better understanding of how every possibility would impact his dentition moving forward. While the primary goal was the removal of the impacted wisdom teeth, I recommended that the additional treatments (parotherapy, fillings, brux splint) be completed as soon as possible – however, these would require further consent at additional consultations.

Result

Overall, the patient was very satisfied with the clarity of the medical briefing and was able to give a much better quality of informed consent due to the use of the CS 8200 3D Neo Edition. The system offers speed, precision and intuitive use, and as my first CBCT system it was remarkably easy to learn how to use. As mentioned before, the excellent quality of the X-rays and the fact that the patient could view them on screen made a big difference to this case - I had a lot more confidence as I had all the information I needed and gaining treatment acceptance was very straightforward as the patient was properly informed and had a much more detailed understanding of his particular needs.

I also liked the fact that there was no need to make an extra appointment with the patient to make a precise diagnosis and explain everything in detail as I had the images and the possibility to easily explain the treatment options with the CS Imaging 8 software immediately at my fingertips. I would usually refer out for CBCT images, and this slows the treatment process down. With the CS 8200 3D Neo Edition it's all instant and there when I need it.

Ultimately, the CS 8200 3D Neo Edition is a fantastic system that has completely transformed my workflows and optimised the way I provide treatment in practice. Not only is it easy to use and capable of capturing dynamic, high-quality images, but it also boasts a number of innovative features that have revolutionised the diagnostic process, which has made me a more confident clinician.

About the Author



Dr. Hubertus Schindler

Dr. Schindler first qualified as a dental technician in 1998. He then studied human medicine and then later dentistry at the University Hospital in Vienna, during which time he also worked as a demonstrator/lecturer in the anatomical department at the Medical University of Vienna. Following graduation, Dr. Schindler has since worked in the University Dental Clinic in Vienna, opened his own private practice in Wiener Neudorf and undertaken advanced training in orthodontics, implantology and oral surgery.

For more information, visit [carestreamdental.com/en-gb/](https://www.carestreamdental.com/en-gb/)

For the latest news and updates, follow Carestream Dental on social media.

